

Ageing Horses by Their Teeth

Being able to pinpoint age within a fairly narrow range can be of use to owners of unregistered horses or horses whose age is unknown for any reason. Many health and nutrition management decisions are directly related to age and dental wear, making it even more important for all horse owners to have a general understanding of how a horse's mouth changes with age. From a historical perspective up until recently when organized associations started keeping birth dates on registered horses, most horse professionals took great pride in their ability to determine age by examining the teeth of any horse. Aging the horse by its teeth is not an exact science, but changes do occur that can help determine approximate age, and anyone can learn the basics.

To use as a reference guide, Figures 1 and 2 indicate the names of the teeth.

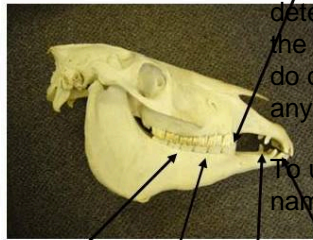
Horses under 5 years of age go through some very typical dental changes. With foals a good rule of thumb to remember is that their milk teeth, or deciduous teeth, erupt, or come in, following a simple timetable of 8 days, 8 weeks and 8 months. Here is how it works. Foals are born either without teeth or with four central incisors, two on the top and two on the bottom. If the central incisors are not present at birth, they usually erupt within 8 days. The intermediate incisors erupt by 8 weeks (Figure 3) and the corner incisors by about 8 months. These are deciduous or temporary milk teeth that will be shed as the young horse ages. The deciduous teeth can be distinguished from permanent teeth because they are wider than they are tall and they have shallow roots. Twelve premolars will also erupt within 2 weeks of age, three on each side of the top and bottom jaws. However, premolars are typically not used in aging horses as they are more difficult to view.

Other dental changes occur in yearly increments and the young horse's mouth changes like a child's does as they shed their deciduous teeth. This systematic shedding of deciduous teeth is what we use to "age" horses until they have all of their permanent teeth at 5 years of age.

Pattern of Deciduous Tooth Shedding

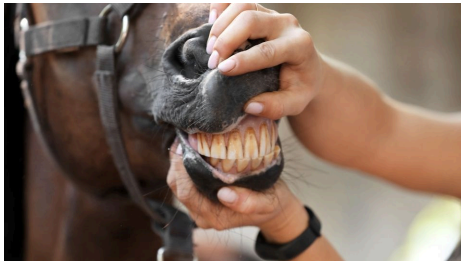At 2 ½ years the horse's deciduous central incisors are pushed out of the way as the permanent centrals erupt from below (Figures 4 and 5). At 3 years the upper central and lower central incisors have grown out enough to meet, and therefore, begin to grind against one another. This is referred to as being "in wear." These wear patterns will be

Wolf tooth does not appear in this picture in perspective up until recently when organized associations started keeping birth dates on registered horses, most horse professionals took great pride in their ability to determine age by examining the teeth of any horse. Aging the horse by its teeth is not an exact science, but changes do occur that can help determine approximate age, and anyone can learn the basics.

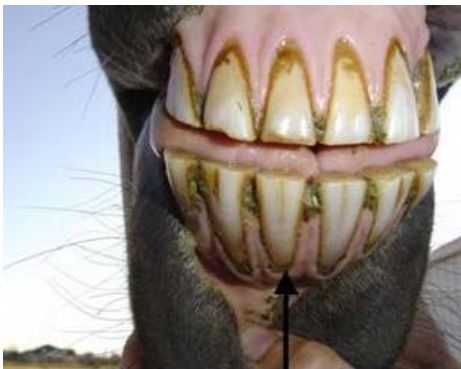

Incisors

Figure



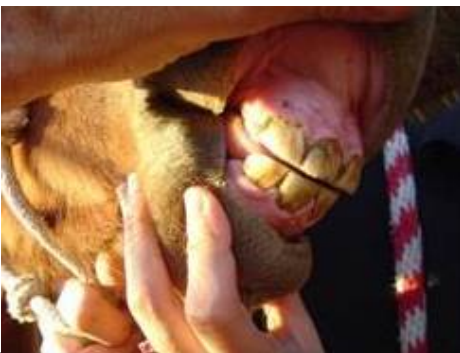1. Horse's



Incisors

teeth.

Figure 2.



Incisors.

Figure 3.

A weanling with central and intermediate deciduous teeth in, but corners incisors have not erupted yet. This means it is between 8 weeks and 8 months of age.

used later in the horse's life to help determine age. At 3 ½ years the intermediate incisors will be shed, and at 4 years of age they will be in wear. At 4 ½ years the corner incisors will be shed, and 6 months later, they will be in wear. See Table 1 for list of dental changes.

Table 1. Average Ages of Tooth Eruption in Horses

	Tooth	Eruption
Deciduous	1st incisor (or centrals)	birth or first week
	2nd incisor (or intermediate)	4 to 6 weeks
	3rd incisor (or corners)	6 to 9 months
	1st premolar	birth or first 2 weeks for all premolars
	2nd premolar	
	3rd premolar	
Permanent	1st incisor (or centrals)	2 ½ years
	2nd incisor (or intermediate)	3 ½ years
	3rd incisor (or corners)	4 ½ years
	Canine (or bridle)	4-5 years
	1st premolar (or wolf tooth)	5-6 months
	2nd premolar	2 ½ years
	3rd premolar	3 years
	4th premolar	4 years
	1st molar	9-12 months
	2nd molar	2 years
3rd molar	3 ½-4 years	

Credit: Table from Horses by J. Warren Evans

Male horses have four canine teeth (tushes) located between their corner incisor and the molars. Mares will

occasionally have canine teeth, but usually these are not as developed and all four may not be present. These teeth appear during the horse's 4-year-old year. They should not be confused with wolf teeth which are very shallowly rooted and found adjacent to the first premolar.

Wolf teeth are commonly extracted as they may interfere with the bit. Canine teeth are not extracted under normal circumstances. (Refer to Utah State University Extension's Equine Dental Care fact sheet for more information on dental care.) Horses are considered to have a "full mouth" at 5 years old, which means that all permanent teeth have erupted and are in wear.

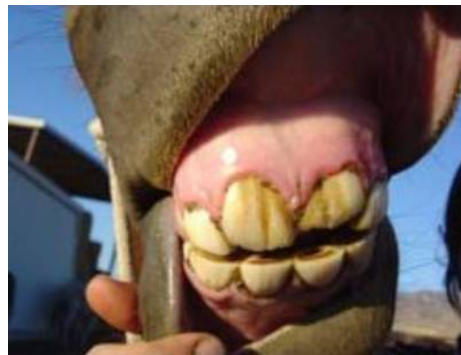

Figure 4. A horse at 2 ½ years old. Top central incisors are permanent but not in wear but bottom centrals are still deciduous.

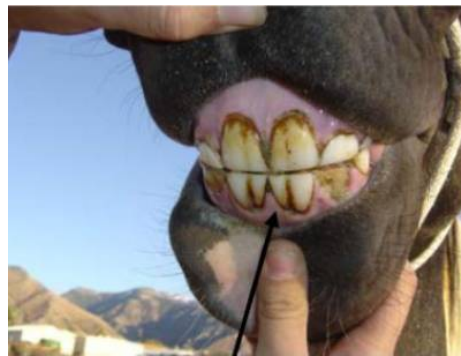

Figure 5. A horse at 3 ½ years of age. Centrals are permanent, and intermediates are ready to fall out.

Other Factors to Determine Age

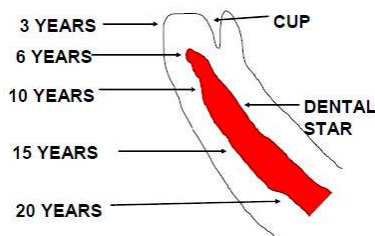
Once all permanent teeth are present, other indicators assist with determining age.

Grinding Surfaces

On the grinding surface of the incisors, a cup is seen as an indented area with a dark center in the middle of each tooth. The cups disappear from the bottom central incisors at 6 years of age, the intermediates at 7 years

and the corners at 8 years. The top incisors lose the cups from central to corners at 9, 10, and 11 years of age, respectively. The term “smooth mouthed horse” applies to a horse 12 years of age or older when all cups are gone, and the grinding surface is smooth (Figures 6a and 6b).

Next to appear on the grinding surface of the incisors is a dental star or yellowish-colored spot. It appears more toward the front of the teeth (closer to the lips) than the cups (Figure 6a). At first this star is rectangular in appearance, but as the horse ages it becomes more rounded and moves to the center of the tooth. The dental star will appear in the central incisors at 8 years of age, intermediates at 9 years, and corners at 10 years.



star and cup.

Figure 6a. Dental

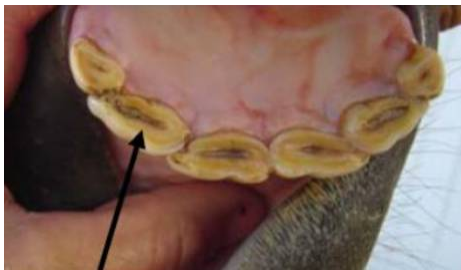

Figure 6b. Cups seen in a young horse of 6 years of age as all cups are present.

The shape of the grinding surface, amount of tooth seen below the gum line, and angle of the teeth change with age. A horse under 9 years of age will have a rectangular grinding surface, a horse from 9 years to mid-teens will have a more rounded grinding surface, while a horse in its later teens or older will have a triangular surface (Figures 7a and b).

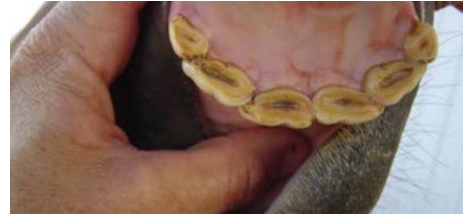

Figure 7a. Young horse's mouth with cups and rectangular table or grinding surface.

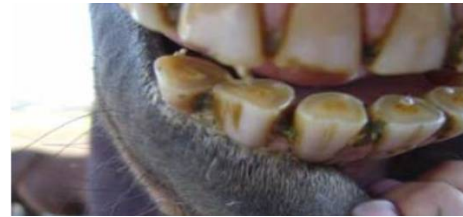

Figure 7b. Old horse's mouth with dental stars and triangular table.

The younger horse will show a shorter tooth visible below the gum line, while a term used for the older horse is “long in the tooth” due to more visible tooth. When viewed from the side with lips parted, the young horse will exhibit a more vertical alignment to the incisors, while an older horse will have more of an angle with a more protruded appearance (Figures 8a and 8b).

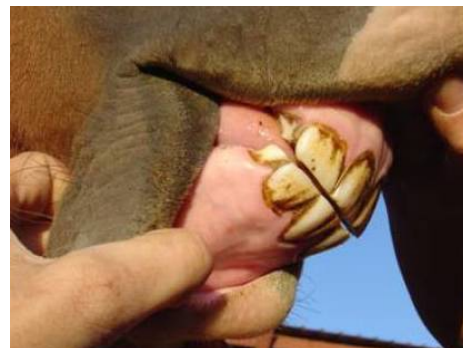

Figure 8a. Young horse with a more vertical profile and less length of tooth visible.

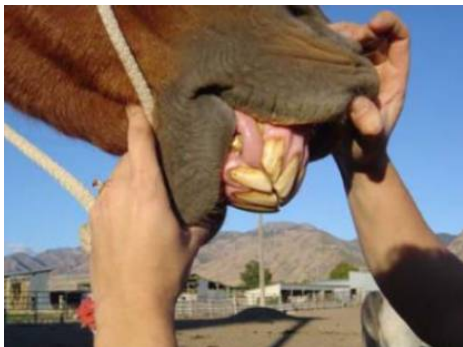

Figure 8b. Older horse with a more angled profile and more length of tooth visible.

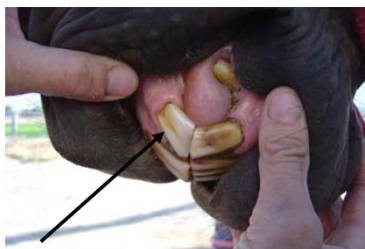

Figure 9. Galvayne's groove.
Galvayne's Groove

A more subtle indicator that can assist with aging the horse over 10 years of age is the Galvayne's Groove (Figure 9). This is a groove that appears near the gum line of the corner incisor. It begins at the center of the outer surface of the tooth in a 10-year-old. At 15 years the groove extends halfway down the tooth; at 20 years it extends the entire length of tooth; at 25 years the upper half of the groove is gone so a groove appears only in the bottom half; and at 30 years the groove is completely gone.

Hook

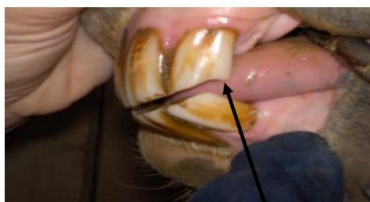

Figure 10. This mare has hook at 11 years old due to a lack of opposing surface at the back edge of the top molar.

Another subtle indicator on the same corner tooth is the 7- and 11-year hook. As the mouth changes shape the rear of the top and bottom corner incisors may not meet, allowing for a hook to form on the top incisor (Figure 10). The first time this hook appears is during the 7-year-old

year and it will disappear at 9 years of age. It will reappear at 11 years of age and may remain through the mid-teens.

These guidelines for aging by dental wear can vary depending on what the horse is eating and on vices. For example, horses that crib can wear down the top incisors, interfering with normal dental wear. While all horses do not follow the rules, these guidelines can be useful tools in evaluating a horse's age.

References

- Jeffrey, D. (1996). *Horse dentistry, the theory and practice of equine dental maintenance*. Norfolk Printing Co.
- Evans, J.W. (1981). *Horses*. San Francisco: W. H. Freeman and Company.

Revised May 2020
Utah State University Extension
Peer-reviewed fact sheet

Authors

Revised by Karl Hoopes, DVM, Utah State University Equine Extension Specialist
Originally written by Patricia A. Evans, Ph.D., and Nancy Jack, Ph.D.